



Summary Feedback

(Combined feedback broadcasted multiple time this week)

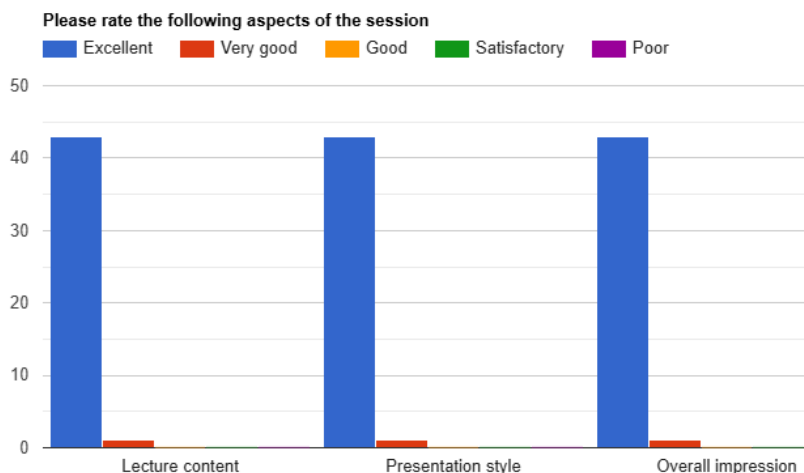
PRE-RECORDED: Basildon FRCR 2B 'A to Zee' Course 2020

Session 11/36

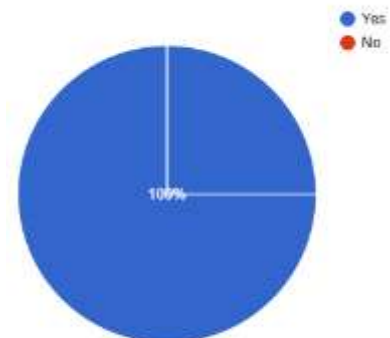
**MSK for FRCR
Infection, AVN & Miscellaneous
(11th & 12th April 2026)
Lecturer: Sami Khan**

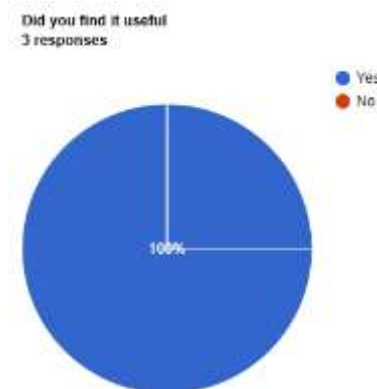
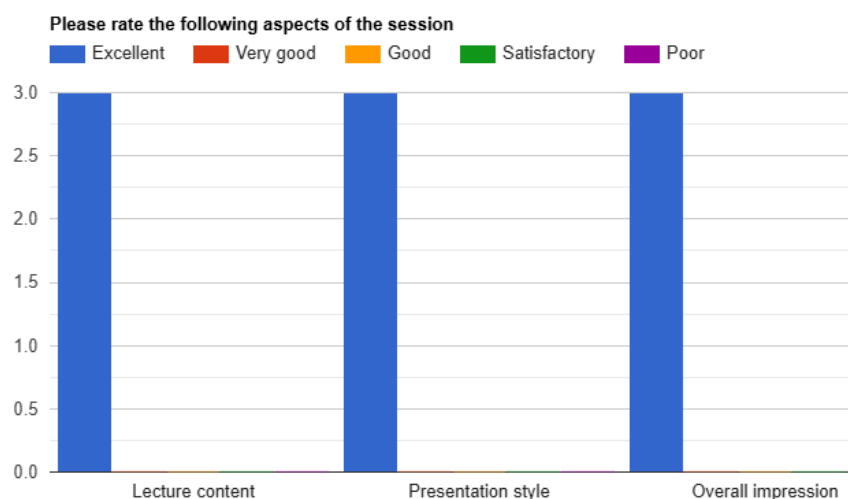
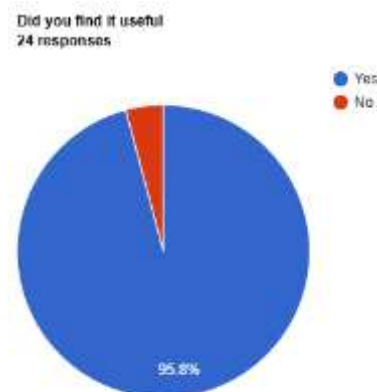
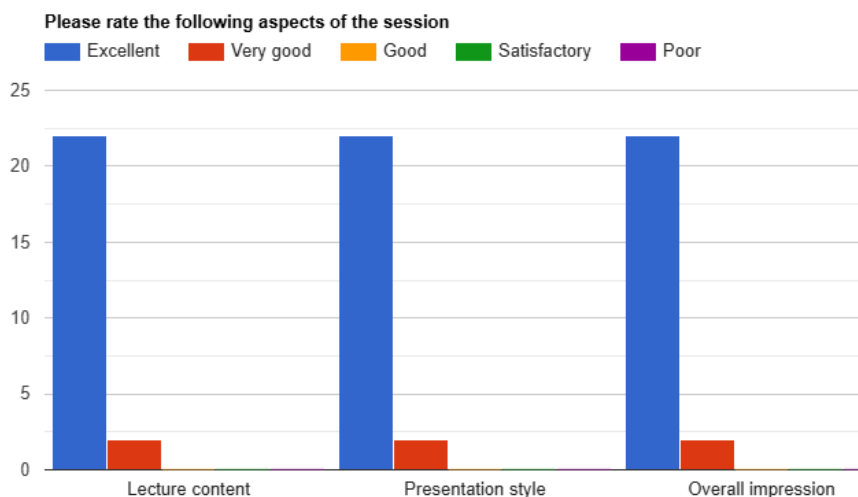
Summary Points:

- Total Attendees: 301 from 36 Countries (Australia, Austria, Bahrain, Bangladesh, Canada, Dominica, Egypt, Ethiopia, Ghana, Hong Kong, India, Indonesia, Iran, Jordan, Kenya, Korea, Republic of, Malaysia, Myanmar, Nigeria, Norway, Oman, Pakistan, Qatar, Saudi Arabia, Singapore, South Africa, Sri Lanka, Sudan, Swaziland, Thailand, Türkiye, UAE, UK, Ukraine, Yemen, Zimbabwe).
- Total duration: 3 hours (each session broadcasted thrice during the week)
- Total feedback received from 71 participants, from three different broadcasts



Did you find it useful
44 responses





Testimonials


- Important teaching points and interesting cases as usual. The topics are selected in a manner to help us develop our knowledge for exam preparation as well as routine practice (Ethiopia).
- Such a helpful and brilliant session. Repeating this session was very useful and helped us to gain more and more; many thanks (Egypt).
- Clear explanation of key concepts – The lecture presented complex topics in a simple and understandable way, making it easier to grasp the fundamentals (Pakistan).
- This is the best teaching platform (South Africa).
- The cases presented and the reaction between the candidate and the presenter were useful (Qatar).
- Golden pearls of revision were useful (UK).
- I am watching these sessions again, and I can still watch them again. These sessions are full of knowledge, and we are learning every time when we watch them (Pakistan).
- Immediate feedback from Dr. Khan was most useful (Hong Kong).
- The cases and concepts were useful (India).

- Every aspect of the lecture was useful (Nigeria).
- All the session was useful (Australia).
- It's great (Yemen).
- It was excellent (Yemen).
- Excellent cases and explanation by Dr. Sami Khan! (UK).
- Excellent cases with excellent differentials (Myanmar).
- The interesting cases and teaching points were useful (Canada).
- I love to see the cases for reviewing my knowledge (Thailand).
- Great teaching as always (Türkiye).
- Really good cases (UK).
- All were useful (Yemen).
- The images were very demonstrative (UAE).
- Great cases and theory summary slides were useful (UK).
- Brilliant session as always (Pakistan).
- Thank you to presenter and team (UK).
- Awesome (Indonesia).
- Perfect (UK).
- Nice session (Pakistan).
- Helpful session (India).
- Awesome (Yemen).
- Thank you so much. Great session, great learning (Pakistan).
- 10/10 (UK).
- Excellent (Yemen).
- Demonstrating the findings was useful (UAE).
- Excellent teaching session (Nigeria).
- Nice session (Egypt).
- Viva practice, differentials and MRI sequences were most useful (UK).
- Excellent case description (Pakistan).
- Thank you very much for every word of this great session (Pakistan).
- Great exam oriented cases and teaching tips (Saudi Arabia).
- Great (Malaysia).
- Selection of cases was useful (UAE).
- Very good cases (UAE).
- Very elaborate (India).
- I like those slides where differentials of syphilis were discussed (Pakistan).
- Case base study approach with diagrams was useful (UK).
- Many differentials were useful (Egypt).
- MSK infections were useful (South Africa).
- All cases and explanations were useful (Yemen).
- Very helpful session. Thank you (UK).
- The teaching in between cases was useful (Zimbabwe).
- excellent spectrum of cases (UK).
- Well-presented teaching cases (Austria).
- Nice lecture (Sudan).
- Case selection was useful (UK).
- Brilliant session as always (Pakistan).
- Great teaching (Pakistan).

- Awesome (UAE).
- Excellent as always (Thailand).
- Very helpful (India).
- All aspects are perfect (UK).
- Very useful (Yemen).
- Wonderful session (Pakistan).
- Great! (Zimbabwe).
- Excellent! (Ethiopia).


Caffey Disease
(Infantile cortical hyperostosis)

- **Age of onset** :9weeks to 4 months (in utero diagnosis)
- **Clinical** : Hyperirritability ,soft tissue swelling, bony cortical thickening



STATdx

1/3



Diagnosis?



STATdx

2/3



The image is a composite slide for a medical presentation. In the top left corner, there is a logo for 'FRCR' (Fellowship of the Royal College of Radiologists). In the top right corner, there is a small video feed showing a man with a mustache, identified as 'Dr. Khan's Teaching'. The main content area is divided into three parts: on the left, an anatomical diagram of the hip joint with a red dot indicating a specific location, labeled 'Intraosseous pressure, rising substantially' and 'Intraosseous pressure, rising substantially'; in the top center, a plain film X-ray of the pelvis; and in the bottom center, an axial MRI scan of the pelvis. At the bottom left, the text 'Radiology Assistant' is visible, and at the bottom right, the text '3/3' is visible.

=====XX=====XX=====